

# Two-year follow-up of first human use of cyanoacrylate adhesive for treatment of saphenous vein incompetence

Jose I Almeida<sup>1</sup>, Julian J Javier<sup>2</sup>, Edward G Mackay<sup>3</sup>,  
Claudia Bautista<sup>4</sup>, Daniel J Cher<sup>5</sup> and Thomas M Proebstle<sup>6</sup>

Phlebology  
0(0) 1–8  
© The Author(s) 2014  
Reprints and permissions:  
sagepub.co.uk/journalsPermissions.nav  
DOI: 10.1177/0268355514532455  
phl.sagepub.com  


## Abstract

**Objectives:** To evaluate the safety and effectiveness of endovenous cyanoacrylate-based embolization of incompetent great saphenous veins.

**Methods:** Incompetent great saphenous veins in 38 patients were embolized by cyanoacrylate bolus injections under ultrasound guidance without the use of perivenous tumescent anesthesia or graduated compression stockings. Follow-up was performed over a period of 24 months.

**Result:** Of 38 enrolled patients, 36 were available at 12 months and 24 were available at 24 months follow-up. Complete occlusion of the treated great saphenous vein was confirmed by duplex ultrasound in all patients except for one complete and two partial recanalizations observed at, 1, 3 and 6 months of follow-up, respectively. Kaplan-Meier analysis yielded an occlusion rate of 92.0% (95% CI 0.836–1.0) at 24 months follow-up. Venous Clinical Severity Score improved in all patients from a mean of  $6.1 \pm 2.7$  at baseline to  $1.3 \pm 1.1$ ,  $1.5 \pm 1.4$  and  $2.7 \pm 2.5$  at 6, 12 and 24 months, respectively ( $p < .0001$ ). Edema improved in 89% of legs ( $n = 34$ ) at 48 hours follow-up. At baseline, only 13% were free from pain. At 6, 12 and 24 months, 84%, 78% and 64% were free from leg pain, respectively.

**Conclusions:** The first human use of endovenous cyanoacrylate for closure of insufficient great saphenous veins proved to be feasible, safe and effective. Clinical efficacy was maintained over a period of 24 months.

## Keywords

Endovenous technique, endovenous laser treatment, endovenous thermal ablation, saphenous vein, varicose veins

**Registration:** This trial was registered in May 2012 (before enrollment began) on clinicaltrials.gov: NCT01603433.

## Introduction

Endovenous thermal ablation (EVTA) has proved to be safe and effective for patients with signs and symptoms related to great saphenous vein (GSV) incompetence. Because of both decreased pain and morbidity and accelerated convalescence compared to high ligation and stripping, the Society for Vascular Surgery and the American Venous Forum clinical practice guidelines have ranked EVTA as first-line therapy.<sup>1</sup> EVTA received a similar recommendation in the UK.<sup>2</sup> While EVTA produces high venous occlusion rates with limited downtime,<sup>3–5</sup> it can cause post-operative pain, bruising and other complications, such as sensory nerve damage. EVTA also requires extra needle punctures to deliver perivenous tumescent anesthesia.<sup>6,7</sup>

Ultrasound-guided foam sclerotherapy has gained popularity because of its low cost and high versatility

as a chemical ablation technique applicable across the entire CEAP spectrum of venous disease. However, primary success rates for catheter-directed sclerotherapy of the GSV are as low as 75%;<sup>8</sup> as such, re-intervention to maintain vein closure is common. Moreover, post-procedure inflammation and brownish skin discoloration are frequently observed. Visual disturbances upon injection of sclerosing agent occur in about

<sup>1</sup>Miami Vein Center, Miami, FL, USA

<sup>2</sup>Vein Center at Physicians Regional, Naples, FL, USA

<sup>3</sup>Mackay Vein Institute, St. Petersburg, FL, USA

<sup>4</sup>Canela Clinic, La Romana, Dominican Republic

<sup>5</sup>Wild Iris Consulting LLC, Palo Alto, CA, USA

<sup>6</sup>Dept. of Dermatology, University Clinic of Mainz, Germany

## Corresponding author:

Thomas M Proebstle, Dept of Dermatology, University Medical Center Mainz, Langenbeckstr. 1, 55131 Mainz, Germany.

Email: thomas.proebstle@web.de

1.5% of cases,<sup>9,10</sup> and stroke related to paradoxical air embolism, although rare, has also been reported.<sup>11–13</sup> The above-described treatment options also suffer from the requirement for postoperative use of graduated compression stockings to support closure of the treated vein and minimize side effects such as hematoma and edema.

A new non-ablative procedure using a proprietary formulation of cyanoacrylate (CA) adhesive delivered endovenously has been recently reported.<sup>14</sup> This treatment reduces some of the aforementioned limitations. CA is widely approved as an implantable medical device for a variety of indications, including arteriovenous malformations and intracranial arterial aneurysms<sup>15</sup> however, these CA-formulations but also other types of glue like human fibrin glue have not been reported to be suitable for saphenous vein embolization. Upon intravascular injection, CA rapidly solidifies via a polymerization reaction and produces an inflammatory vein wall reaction.<sup>16–18</sup> Granulomatous foreign body reaction is observed at 30 days after treatment<sup>19</sup> and fibroblasts can be seen invading the contents of the tunica intima and tunica media at 60 days.<sup>20</sup> Early follow-up after human use of CA for the embolization of incompetent GSVs has been reported.<sup>14</sup> We describe herein 24-month follow-up from this cohort, including both anatomical and clinical results.

## Methods

### Study design

This study's design and treatment protocol have been previously described.<sup>14</sup> In brief, 38 patients with incompetent GSVs and related clinical symptoms were treated with a proprietary CA adhesive (Sapheon, Inc., Morrisville, North Carolina, USA) at a single center (Canela Clinic, La Romana, Dominican Republic) and followed prospectively. Inclusion and exclusion criteria are listed in detail in Table 1. Patients underwent color flow duplex imaging preoperatively, and at 48 hours, and at 1, 3, 6, 12 months following treatment. Venous reflux was defined as retrograde flow of more than 500 ms duration elicited by a provocative calf augmentation maneuver. Here we report the follow-up of this cohort at 24 months. Treatment success was defined as complete occlusion of the treated vein segment using duplex ultrasound or recanalization of <5 cm.<sup>21</sup> Clinical examination including both CEAP and Venous Clinical Severity Score (VCSS) assessments was performed preoperatively, at 48 hours, and at 1, 3, 6, 12 and 24 months following treatment. The protocol was approved by the National Committee of Bioethics

and Health of the Dominican Republic and all patients provided written informed consent.

### Procedure technique

The disposable Sapheon™ Closure System (SCS) includes 5 cc of Sapheon™ cyanoacrylate adhesive (CA) and a Sapheon™ Delivery System (SDS). The SDS consists of a 7-F introducer sheath/dilator, a 5-F delivery catheter, a 3 mL syringe and dispenser gun. The hydrophobic 5-F delivery catheter has a novel configuration with air-filled micro-channels to enhance sonographic visibility. The dispenser gun was designed to deliver 0.08 ml of CA with each trigger pull.

Similar to EVTA, the patient's vasculature was mapped preoperatively under ultrasound guidance and the GSV was accessed percutaneously with a micropuncture introducer kit followed by insertion of a 0.035" J guide wire (Cook, Bloomington, IN, USA). Using ultrasound control (GE, Milwaukee, WI, USA), a 7-F introducer sheath/dilator is advanced to the saphenofemoral junction (SFJ) and positioned 1.5 to 2.0 cm caudal to the SFJ. The 3-ml syringe containing CA extracted from its shipping vial is attached to the delivery catheter. The catheter is primed with the dispenser gun to fill all but the final 3 cm of catheter tubing; this step ensures that the catheter tip is empty upon venous insertion to prevent premature contact of CA with blood. The primed delivery catheter is inserted into the introducer sheath and secured with spin-lock mechanism. Then 5 cm of the catheter tip is exposed distal to the sheath tip and positioned 3–5 cm from the SFJ. CA delivery consists of an initial double CA injection (~0.16 cc) followed by a 3-cm pullback and 3-minute localized compression. Then, repeated injections of 0.08 cc of CA followed by pullbacks of 3 cm and 30-second localized compressions of delivered CA take place until the entire vein is treated. After venous closure is confirmed by ultrasound, the catheter is removed and compression applied to the catheter entry site until hemostasis is achieved. A single small bandage is applied at the puncture site; compression stockings are not used.

Patients were discharged immediately after treatment and instructed to resume normal activities but avoid strenuous exercise until the first follow-up visit (at 24–72 hours after treatment). No ancillary procedures such as phlebectomy or sclerotherapy were permitted in the study protocol until after the 3-month follow-up visit.

### Statistical methods

Standard statistical summaries of patient characteristics were performed. The proportion of patients with

**Table 1.** Inclusion and exclusion criteria. All of the following inclusion criteria must be satisfied in order for a subject to be eligible for enrollment. Subjects who meet any of the following exclusion criteria must be excluded from the study.

---

Inclusion criteria

---

- Males or non-pregnant females >21 years of age but <76 years of age.
- Venous reflux disease in the GSV diagnosed by clinical symptoms, with or without visible varicosities, and confirmed by duplex ultrasound imaging.
- Candidate for surgical closure of a segment of the GSV (Doppler Ultrasound Criteria defined on the Surgical Clearance CRF).
- CEAP classification of C2, C3 or C4.
- Ability to walk unassisted.
- Life expectancy of at least 18 months.
- Weight >110 lbs (50 kg).
- Ability to attend follow-up visits.
- Ability to understand the investigational nature of the treatment, and to provide written informed consent.

Exclusion criteria

- Previous surgical procedure (surgical, thermal, or chemical ablation) associated with the venous segment to be treated.
  - Diameter of index vein (Supine) <3 mm or >12 mm in any segment.
  - Tortuous GSV, which in the opinion of the Investigator will limit catheter placement.
  - Local or systemic infection.
  - Insulin dependent diabetes.
  - Leg obesity impairing the ability to gain access to the treatment leg, and/or apply sufficient compression for treatment.
  - Documented history of superficial or deep thrombophlebitis.
  - Varicosities secondary to pelvic or abdominal tumor.
  - Significant arterial insufficiency; demonstrated by an ABI <0.8 (index leg).
  - Known sensitivity to the cyanoacrylate (CA) adhesive or positive reaction just prior to surgery (by injecting a small peripheral vein with the agent). The Study surgeon will judge the need for the injection and the subject's reaction to the injection on clinical grounds.
  - Formal duplication of the saphenous trunk in the index vein (accessory GSV segments allowed).
  - Hypercoagulable state.
  - Presence of incompetent perforators in the treatment length.
  - History of right ventricular failure.
  - Significant femoral or popliteal vein insufficiency.
  - BMI > 35.
  - Additional procedures in the treatment leg likely required within the 6 months after the investigational procedure.
  - Current participation in another clinical study involving an investigational agent or treatment, or within the 30 days prior to enrollment.
  - Other concurrent medical or other condition (chronic or acute in nature) that in the opinion of the Investigator may prevent safe participation or otherwise render the subject ineligible for the Study.
- 

complete closure of the GSV was calculated using Kaplan-Meier methods. Mean change from baseline in VCSS and CEAP was evaluated using repeated measures analysis of variance. Descriptive analysis of VCSS subdomains was performed in addition. Software analysis was performed with SAS (Cary, NC, USA, Version 9.0) and R.<sup>22</sup>

## Results

A total of 38 patients were enrolled, with median age 51 year (range 26–77). As expected, female gender predominated (n = 29, 76%). Mean body mass index (BMI) was 27.6 (range 22.4–45.3). Subject co-morbidities included hypertension (n = 11), obesity (n = 4), abnormal lipids (n = 4), diabetes (n = 3), drug allergy (n = 2), previous phlebectomy (n = 1) and previous GSV ablation (n = 1). The CEAP classification was C2 (n = 14, 37%), C3 (n = 7, 18%), C4 (n = 16, 42%) and C6 (n = 1,

3% [representing a protocol deviation]). Mean pre-procedure VCSS score was  $6.0 \pm 2.7$  (range 2–17). Mean pre-procedure GSV diameter at the SFJ in the standing position was  $8.0 \pm 2.2$  mm (range 4.1–12.0).

Thirty-eight limbs in 38 patients were treated by four different physicians (JIA JJJ, EGM, TMP). The mean diameter of the treated veins was 6.7 mm with a mid-range of 8.5 mm. Mean GSV treatment length was  $33.8 \pm 9.1$  cm. A mean of 1.3 ml (range 0.6–2.3 ml) of CA glue was delivered. Mean treatment time was 21 minutes (range 14–33). All 38 patients were available for 24- to 48-hour follow-up and follow-up at 1 and 3 months. Thirty-six patients were seen at 6 and 12 months, and 24 patients were seen at 24 months. Follow-up examinations from 3 months on were conducted (by CB). No subject had adjunctive treatment of the target GSV during 24-month follow-up. The study protocol allowed for treatment of symptomatic tributaries 6-months after the index GSV procedure

(ultrasound guided sclerotherapy (UGS), n=3; UGS and phlebectomy, n=1).

As reported previously, the most frequent side effect was phlebitis (6 patients, 16%) with mild pain and erythema. Phlebitis lasted an average of 5.2 days (range 3–14) and was treated with oral non-steroidal anti-inflammatory agents only. One subject had hyperpigmentation over the skin of the treated vein, which was still visible at 24 months. As reported earlier,<sup>14</sup> thread-like thrombus or glue extensions across the SFJ seen at the 48-hour follow-up had all resolved at 3-month follow-up in 21.1% of patients. During follow-up, no patient demonstrated any signs or symptoms of pulmonary embolism or DVT. No additional treatment-related side effects were observed between 6 and 24 months follow-up. No SAE were observed throughout the study.

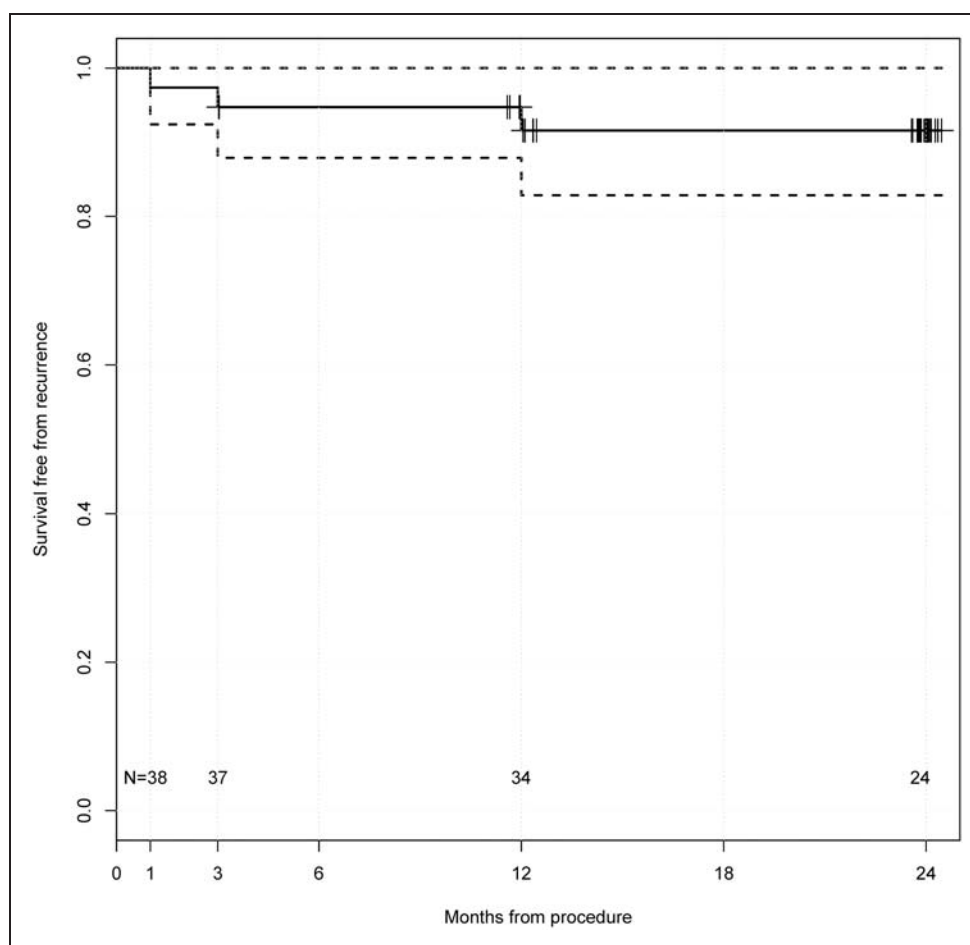
### Anatomical success

Immediately post procedure and at 48-hour follow-up, all patients had complete occlusion of the treated vein

segments as assessed by duplex ultrasound. During follow-up, three patients presented with a GSV recanalization of more than 5 cm at 1, 3 and 6 months, respectively. Life-table analysis (Figure 1) demonstrated a 24-month occlusion rate of 92%. One patient who had partial recanalization at 1 month showed complete recanalization at 3 months. Two partial recanalizations (at 3 and 6 months) occurred at the mid-thigh. No further recanalizations occurred after 12 months. The standard error of the survival curve point estimates was below 0.05 at all times. The remnants of the occluded GSV under ultrasound showed a dense fibrotic but non-inflammatory appearance that decreased in diameter over time reflecting partial degradation of the CA, however, specific measurements were not obtained.

### VCSS

VCSS scores were recorded at baseline and at all follow-up visits. At all postoperative time points, VCSS scores were significantly lower than the preoperative scores (Figure 2). Mean ( $\pm$ SD) VCSS



**Figure 1.** Kaplan-Meier analysis of time to GSV recanalization after endovenous CA. Hash marks represent censored) observations.

improved from 6.1 (2.7) at baseline to 1.3 (1.2) at 6 months. At 24 months VCSS scores were significantly higher than the 6-month nadir but still substantially lower compared to baseline. It should be noted that VCSS takes into account all venous disease, including non-GSV disease and contralateral signs and symptoms.

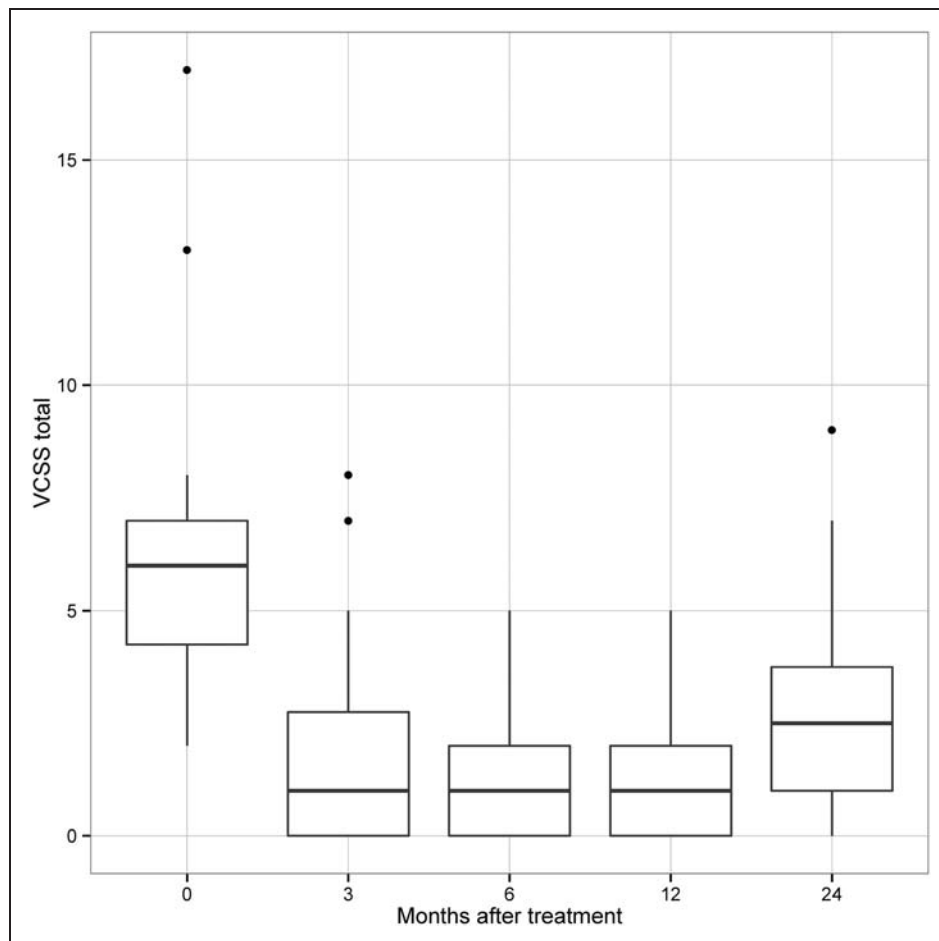
When looking at VCSS subdomains, the proportion of patients who were free from varicose veins, pain and edema increased remarkably (Figure 3). While at baseline no patient was free from varicosities, 47% of patients were free from varicose veins and at 12 and 24 months 50% and 35% showed no varicosities. The proportion of patients with only minimal varicosities (VCSS subdomain scores of 0 or 1) was 24%, 84%, 75% and 65% at baseline, 6, 12 and 24 months, respectively.

Reduction of edema and pain was even more pronounced. The proportion of patients free from edema increased from 42% at baseline to 84% by 6 months and remained high (65%) at 24 months. Similarly, the proportion of patients free from pain increased

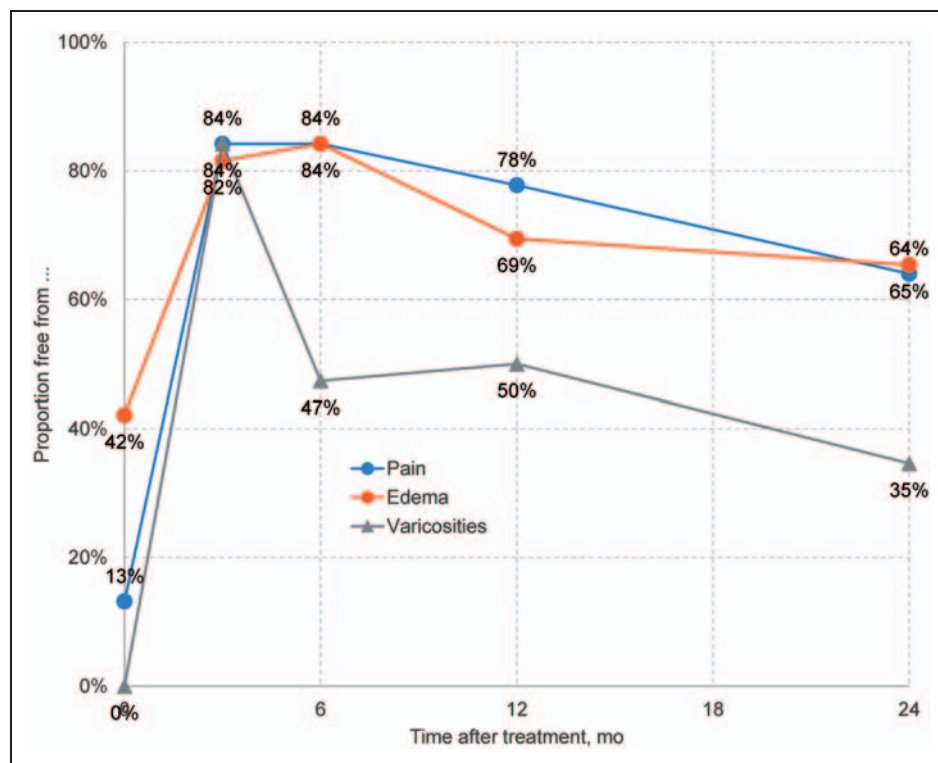
from 13% at baseline to 84% by six months, remaining high (64%) at 24 months. There were no paresthesias.

## Discussion

In this first-in-man study, endovenous CA adhesive for embolization of incompetent GSVs showed both excellent safety, tolerability and mid-term effectiveness. Regarding safety, no serious treatment-related adverse events were observed at any time during follow-up and procedure-related adverse events were uncommon, mild and easily treated by non-steroidal antiphlogistic drugs. In concert with excellent tolerability, CA-embolization appeared to have durable long-term effectiveness (Figure 1). The cumulative occlusion rate of 92% at 12 and 24 months after treatment is comparable to contemporary thermal ablation results.<sup>4,5,23</sup> Only one complete recanalization was observed 3 months after treatment in a patient who presented with a partial recanalization after 1 month. Two additional recanalizations were observed at 3 and 6 months follow-up. The results of



**Figure 2.** Venous Clinical Severity Score (VCSS) at baseline and follow-up.



**Figure 3.** Rate of limbs free from varicose veins (blue) and edema (red) during follow-up.

this study are in line with the findings of other studies on endovenous ablation of GSV reflux which also demonstrated that the majority of recanalization events happened during the first 6 months after treatment.

Not surprisingly, anatomic success in closing incompetent GSVs was associated with clinical improvements. Improvements in VCSS were significant (Figure 2) and similar in degree to those seen after segmental radiofrequency thermal ablation.<sup>24</sup> VCSS improved in all 36 study patients at 6 months follow-up, with a mean (SD) improvement from of 6.1 ( $\pm 2.7$ ) at baseline to 1.1 ( $\pm 1.0$ ). The improvement in VCSS persisted at 12 months but decreased somewhat at 24 months, probably because of progression of underlying disease.

VCSS subdomains also improved (Figure 3). Venous edema improved in almost 90% of treated legs within 48 hours of the procedure,<sup>14</sup> and, more than two-thirds of patients remained free from venous edema at 12 and 24 month follow-up. The VCSS pain subdomain largely paralleled venous edema, with 78% of patients reporting no pain in the treated leg at 12 months follow-up and 64% reporting no pain 12 months later.

Unlike what was done in this study, many physicians combine phlebectomy with saphenous closure in the same session.<sup>25</sup> Consistent with findings of Welch et al.,<sup>26</sup> 47% of legs in this study were free from visible

varicosities and 36% of legs showed limited varicosities at 6 months without additional treatment. At 24 months follow-up, the proportion of patients free from varicosities decreased somewhat, but this was likely due to progression of underlying disease. These findings raise the question of whether concurrent phlebectomy or sclerotherapy of tributaries at the time of GSV ablation is required.

Tumescent anesthesia provides thermal protection to perivenous tissues; however, its administration requires several percutaneous injections,<sup>25</sup> which can cause injury. Saphenous vein wall perforations,<sup>27</sup> perforations of the fascial compartment surrounding the saphenous vein, or shearing of subcutaneous reticular veins or arterioles by the tumescent needle potentially add to post-procedure pain and bruising. The needle may also damage the saphenous or sural nerves when treating below the knee.

In contrast, endovenous CA is a non-thermal embolic adhesive, and as seen in this cohort of patients resulted in a low rate of post-procedure pain, bruising and paresthesias. Because endovenous CA endoluminally bonds the vein wall, perivenous extravasation of post-ablation elements and needle injury along the inner thigh and calf are avoided. Excellent clinical results were seen with this novel vein closure technique without the need for perivenous tumescent anesthesia and post-procedure compression stockings.

## Conclusion

In summary, first human use of endovenous CA embolization for closure of insufficient GSVs proved to be feasible, safe and highly effective. Initial clinical and anatomical results were durable over a follow-up period of 24 months. Larger cohort studies and comparative randomized trials are needed to confirm these findings.

## Funding

The study was funded by Sapheon, Inc., Morrisville, NC 27560, USA.

## Conflict of interest

E Mackay is a stockholder for Sapheon Inc. C Bautista reports personal fees from VASCULAR DEVICE PARTNERS, during the conduct of the study. D Cher reports personal fees and other from Wild Iris Consulting Inc, during the conduct of the study; personal fees and other from Wild Iris Consulting LLC, outside the submitted work. TM Proebstle reports grants from Sapheon Inc, during the conduct of the study; and stockholder of Sapheon Inc. All other authors report no conflict of interest.

## References

- Gloviczki P, Comerota AJ, Dalsing MC, et al. The care of patients with varicose veins and associated chronic venous diseases: clinical practice guidelines of the Society for Vascular Surgery and the American Venous Forum. *J Vasc Surg* 2011; 53: 2S–48S.
- National Institute for Health and Care Excellence. Varicose veins in the legs. The diagnosis and management of varicose veins [Internet]. National institute for Health and Care Excellence; 2013, guidance.nice.org.uk/cg168 (accessed April 2014).
- Proebstle TM, Krummenauer F, Gül D, et al. Nonocclusion and early reopening of the great saphenous vein after endovenous laser treatment is fluence dependent. *Dermatol Surg* 2004; 30: 174–178.
- Van den Bos R, Arends L, Kockaert M, et al. Endovenous therapies of lower extremity varicosities: a meta-analysis. *J Vasc Surg* 2009; 49: 230–239.
- Rasmussen LH, Lawaetz M, Bjoern L, et al. Randomized clinical trial comparing endovenous laser ablation, radiofrequency ablation, foam sclerotherapy and surgical stripping for great saphenous varicose veins. *Br J Surg* 2011; 98: 1079–1087.
- Almeida JI, Kaufman J, Göckeritz O, et al. Radiofrequency endovenous ClosureFAST versus laser ablation for the treatment of great saphenous reflux: a multicenter, single-blinded, randomized study (RECOVERY study). *J Vasc Interv Radiol* 2009; 20: 752–759.
- Proebstle TM, Vago B, Alm J, et al. Treatment of the incompetent great saphenous vein by endovenous radiofrequency powered segmental thermal ablation: first clinical experience. *J Vasc Surg* 2008; 47: 151–156.
- Devereux N, Recke AL, Westermann L, et al. Catheter-directed foam sclerotherapy of great saphenous veins in combination with pre-treatment reduction of the diameter employing the principals of perivenous tumescent local anesthesia. *Eur J Vasc Endovasc Surg* 2014; 47: 187–195.
- Guex J-J, Allaert F-A, Gillet J-L, et al. Immediate and midterm complications of sclerotherapy: report of a prospective multicenter registry of 12,173 sclerotherapy sessions. *Dermatol Surg* 2005; 31: 123–128; discussion 128.
- Gillet J-L, Guedes JM, Guex J-J, et al. Side-effects and complications of foam sclerotherapy of the great and small saphenous veins: a controlled multicentre prospective study including 1,025 patients. *Phlebology* 2009; 24: 131–138.
- Forlee MV, Grouden M, Moore DJ, et al. Stroke after varicose vein foam injection sclerotherapy. *J Vasc Surg* 2006; 43: 162–164.
- Bush RG, Derrick M and Manjoney D. Major neurological events following foam sclerotherapy. *Phlebology* 2008; 23: 189–192.
- Ma RWL, Pilotelle A, Paraskevas P, et al. Three cases of stroke following peripheral venous interventions. *Phlebology* 2011; 26: 280–284.
- Almeida JI, Javier JJ, Mackay E, et al. First human use of cyanoacrylate adhesive for treatment of saphenous vein incompetence. *J Vasc Surg* 2013; 1: 174–180.
- Linfaente I and Wakhloo AK. Brain aneurysms and arteriovenous malformations: advancements and emerging treatments in endovascular embolization. *Stroke* 2007; 38: 1411–1417.
- Levrier O, Mekkaoui C, Rolland PH, et al. Efficacy and low vascular toxicity of embolization with radical versus anionic polymerization of n-butyl-2-cyanoacrylate (NBCA). An experimental study in the swine. *J Neuroradiol* 2003; 30: 95–102.
- Vinters HV, Galil KA, Lundie MJ, et al. The histotoxicity of cyanoacrylates. A selective review. *Neuroradiology* 1985; 27: 279–291.
- Spiegel SM, Viñuela F, Goldwasser JM, et al. Adjusting the polymerization time of isobutyl-2 cyanoacrylate. *Am J Neuroradiol* 1986; 7: 109–112.
- Min RJ, Almeida JI, McLean DJ, et al. Novel vein closure procedure using a proprietary cyanoacrylate adhesive: 30-day swine model results. *Phlebology* 2012; 27: 398–403.
- Almeida JI, Min RJ, Raabe R, et al. Cyanoacrylate adhesive for the closure of truncal veins: 60-day swine model results. *Vasc Endovascular Surg* 2011; 45: 631–635.
- Khilnani NM, Grassi CJ, Kundu S, et al. Multi-society consensus quality improvement guidelines for the treatment of lower-extremity superficial venous insufficiency with endovenous thermal ablation from the Society of Interventional Radiology, Cardiovascular Interventional Radiological Society of Europe, American College of Phlebology and Canadian

- Interventional Radiology Association. *J Vasc Interv Radiol* 2010; 21: 14–31.
22. R Core Team. R: A Language and Environment for Statistical Computing [Internet]. Vienna, Austria: R Foundation for Statistical Computing; 2013, <http://www.R-project.org/> (accessed April 2014)
  23. Biemans AAM, Kockaert M, Akkersdijk GP, et al. Comparing endovenous laser ablation, foam sclerotherapy, and conventional surgery for great saphenous varicose veins. *J Vasc Surg* 2013; 58: 727–734.e1.
  24. Proebstle TM, Alm J, Göckeritz O, et al. Three-year European follow-up of endovenous radiofrequency-powered segmental thermal ablation of the great saphenous vein with or without treatment of calf varicosities. *J Vasc Surg* 2011; 54: 146–152.
  25. Mekako A, Hatfield J, Bryce J, et al. Combined endovenous laser therapy and ambulatory phlebectomy: refinement of a new technique. *Eur J Vasc Endovasc Surg* 2006; 32: 725–729.
  26. Welch HJ. Endovenous ablation of the great saphenous vein may avert phlebectomy for branch varicose veins. *J Vasc Surg* 2006; 44: 601–605.
  27. Min RJ, Zimmet SE, Isaacs MN, et al. Endovenous laser treatment of the incompetent greater saphenous vein. *J Vasc Interv Radiol* 2001; 12: 1167–1171.
  28. Kabnick LS. Outcome of different endovenous laser wavelengths for great saphenous vein ablation. *J Vasc Surg* 2006; 43: 88–93.